

## FROM SKIN INFECTIONS TO BARIATRIC SURGERY IN PATIENTS WITH ENDOCRINE TUMOURS

Assist. Prof. Florica Sandru<sup>1,2</sup>, MD, PhD, Lecturer Ana Valea<sup>3,4</sup>, MD, PhD,  
Assist. Prof. Simona Elena Albu<sup>2,5</sup>, MD, PhD, Lecturer Mihai Cristian Dumitrascu<sup>2,5</sup>, MD, PhD,  
Lecturer Mara Carsote<sup>2,6</sup>, MD, PhD

<sup>1</sup> Elias Emergency University Hospital, Bucharest, Romania

<sup>2</sup> Carol Davila University of Medicine and Pharmacy, Bucharest, Romania

<sup>3</sup> Clinical County Hospital, Cluj-Napoca, Romania

<sup>4</sup> „Iuliu Hatieganu“ University of Medicine and Pharmacy, Cluj-Napoca, Romania

<sup>5</sup> Emergency University Hospital, Bucharest, Romania

<sup>6</sup> „C.I. Parhon“ National Institute of Endocrinology, Bucharest, Romania

### ABSTRACT

Obesity is associated with multiple complications like cardiovascular, oncologic, including skin infections potentially with a more severe evolution than in subjects with normal weight. We aim is to introduce two cases of females who initially presented with skin infections associating obesity and two different types of endocrine tumours; both of them underwent bariatric surgery. One case of a young female who had acne and menses anomalies was confirmed with macroprolactinoma and treated with cabergoline with menses control. For obesity she had bariatric surgery with weight and acne control but associating long term hypovitaminosis D. The second case is a menopausal woman with metabolic syndrome and different persistent skin infections in association with features of cardio-metabolic anomalies which were confirmed as adrenal Cushing's syndrome and referred for unilateral adrenalectomy. The improvement of mentioned parameters was not associated with obesity control so bariatric surgery was done. She suffered a shoulder fracture and she was confirmed with osteoporosis (a lumbar T-score of -3.3 SD). The values of 25-hydroxyvitamin D remained normal only under oral replacement with vitamin D supplements and zoledronic acid was added. Obesity underlines heterogeneous aspects including dermatological, metabolic, cardiovascular and endocrine conditions; some of them are dramatically improved after bariatric surgery, yet not hipovitaminosis D and osteoporosis especially in menopausal women. The prolactin excess, Cushing's disease or just obesity itself may cause repeated skin infections or acne.

**Keywords:** skin, acne, bariatric surgery

### Abbreviations

BMI = body mass index

DXA = Dual-Energy X-Ray Absorptiometry

SD = standard deviation

### INTRODUCTION

Obesity is associated with multiple complications like cardiovascular, oncologic, including skin infections potentially with a more severe evolution than subjects with normal weight (1,2). Also some particular types of fractures are more frequent with or without the implication of type 2 diabetes mellitus and/or hyperlipemia, obesity (3,4). Bariatric surgery dramatically improve the cardio-metabolic profile

and potentially the frame of infections (if malnutrition or malabsorption is not present), not necessary it reduces the risk of osteoporotic fractures (5,6).

### AIM

We aim to introduce two cases of females who initially presented with skin infections associating obesity and two different types of endocrine tumours; both of them underwent bariatric surgery.

Corresponding author:  
Lecturer Ana Valea  
E-mail: ana74us@yahoo.com

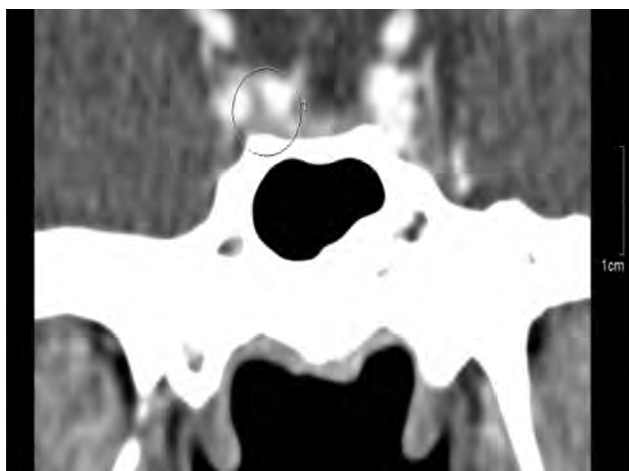
## MATERIAL AND METHOD

This is a cases series introducing the medical background and the endocrine panel.

### CASES DATA

#### Case report 1

This is a 35 years old female who is non-smoker coming from non-endemic area. Her medical history is negative both for family and personal. She started to manifest menses delay and acne. She has a body mass index (BMI) of 33 kg/sqm. Further on the endocrine check up was required. A level of prolactin 7 times above normal limits and a pituitary macroadenoma of 1.5 cm (centimetre) confirmed a prolactinoma. Therapy with cabergoline of different regimes was introduced starting with progressive high doses up to 3 mg/week. After first year the tumour became microprolactinoma (Figure 1). Since the therapy started the menses normalized. Yet BMI was not controlled so she underwent bariatric surgery with a weight control as well as a remission of acne. However, low levels of 25-hydroxyvitamin D required replacement with high doses of cholecalciferol 2000 UI per day. Further on she had a successful pregnancy requiring also vitamin D substitution (the highest levels of 25-hydroxyvitamin D were 27 ng/ml, normal between 30 and 100 ng/ml under daily 2,000 UI of vitamin D).



**FIGURE 1.** Computed tomography of the pituitary gland: Treated macroprolactinoma with cabergoline on a adult female of reproductive age

#### Case report 2

The second case is a 63 year old non-smoking female with metabolic syndrome and different persistent skin infections. Further on she was actually

confirmed with an adrenal Cushing's syndrome and referred for unilateral adrenalectomy. The improvement of cardio-metabolic parameters was not associated with grade 3 obesity controls thus she was referred for bariatric surgery. Further on she suffered a shoulder fragility fracture and she was confirmed with the diagnosis of osteoporosis. Central DXA revealed a minimum T-score of -3.3 SD (Figure 2). The values of 25-hydroxyvitamin D remained normal only under oral replacement with vitamin D and also she was offered zoledronic acid as specific anti-osteoporotic drug. Life follow-up is required.

### DISCUSSION

We introduce some aspects which are revealed by the cases series.

#### *Bariatric surgery and vitamin D*

Bariatric surgery has an explosive use during the last years (7,8,9). Even it saves lives, some complications (that are difficult to be considered "iatrogenic") are identified especially in relationship with nutrients and vitamins loss (7,8,9). Bone might also suffer since 75% of the patients have hypovitaminosis D and require lifelong vitamin D substitution with high doses (7,8,9). Otherwise, two thirds of untreated patients with vitamin D replacements might manifest clinical aspects of tetania (7,8,9). In these cases both of our patients experienced post-operative low vitamin D levels. Despite hypovitaminosis D weight control was achieved and also skin lesions control.

#### *Prolactinoma and obesity*

The young female cased associated obesity and macroprolactinoma. Some studies pointed out that the patients with prolactin producing macroadenomas have a higher risk of obesity (independent of features related to central hypogonadism), but it is not a general observation (10,11).

#### *Autonomous cortisol secretion and bone status*

The menopausal woman we introduced actually was diagnosed with Cushing's disease starting from cardiovascular and metabolic complications including obesity. Yet, the weight control was not obtained after the normalization of adrenal function. Despite the fact that obesity is currently a worldwide medical problem and associated economic burden, the underlying endocrine causes due to endocrine tumours represent only a small percent of it (12). The autonomous cortisol production, regardless clinical or subclinical, is correlated with a higher risk of high blood pressure, increased body mass index, and bone loss independent of patients'

Region	<sup>1</sup> BMD (g/cm <sup>2</sup> )	<sup>2</sup> Young-Adult (%) T-Score		<sup>3</sup> Age-Matched (%) Z-Score		BMC (g)	Area (cm <sup>2</sup> )	Width (cm)	Height (cm)
T12	0,877	-	-	-	-	9,22	10,51	3,8	2,73
L1	0,842	74	-2,4	80	-1,8	9,32	11,08	4,0	2,78
L2	0,739	62	-3,8	66	-3,2	8,03	10,86	3,7	2,95
L3	0,797	66	-3,4	71	-2,7	9,82	12,31	4,0	3,05
L4	0,849	71	-2,9	76	-2,3	11,84	13,95	4,2	3,30
L2-L3	0,770	64	-3,6	69	-2,9	17,85	23,18	3,9	6,00
L2-L4	0,800	67	-3,3	71	-2,7	29,68	37,12	4,0	9,30

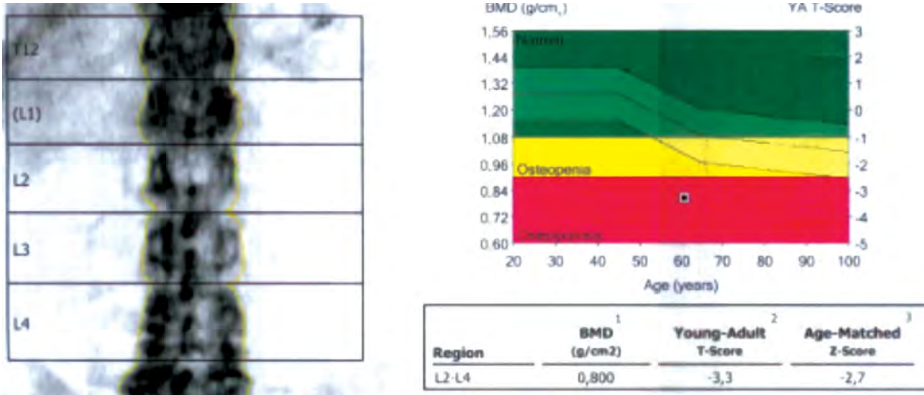


FIGURE 2A. Lumbar spine

Region	<sup>1</sup> BMD (g/cm <sup>2</sup> )	<sup>2</sup> Young-Adult (%) T-Score		<sup>3</sup> Age-Matched (%) Z-Score		BMC (g)	Area (cm <sup>2</sup> )
Neck	0,764	74	-2,0	83	-1,1	3,75	4,91
Upper Neck	0,640	78	-1,5	87	-0,8	1,54	2,41
Lower Neck	0,883	-	-	-	-	2,21	2,50
Wards	0,520	57	-3,0	70	-1,8	1,39	2,67
Troch	0,720	85	-1,1	91	-0,6	10,81	15,01
Shaft	1,043	-	-	-	-	14,77	14,16
Total	0,860	85	-1,2	91	-0,6	29,32	34,08

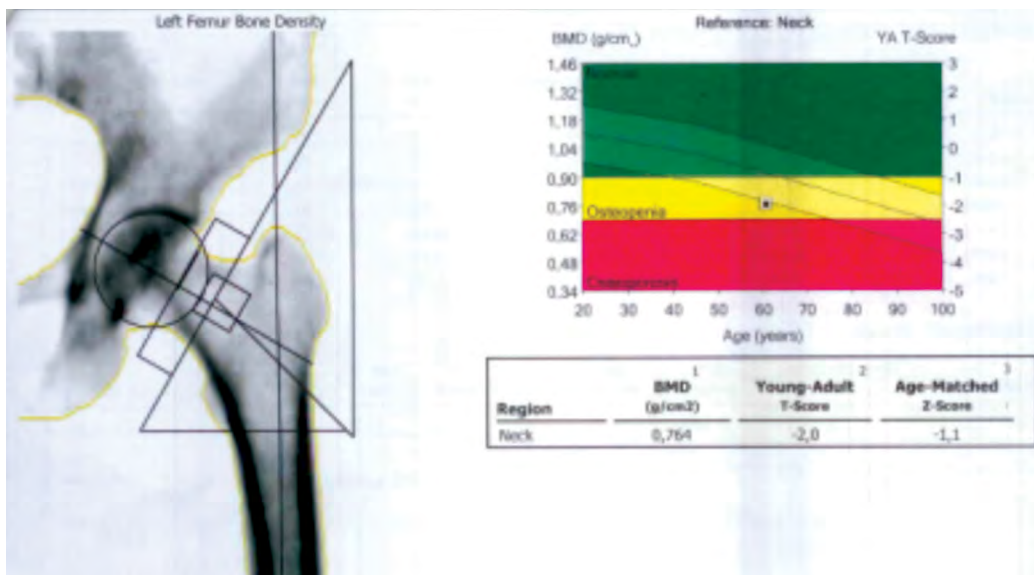


FIGURE 2B. Total hip and femoral neck

Region	<sup>1,3</sup> BMD (g/cm <sup>2</sup> )		<sup>2</sup> Young-Adult (%) T-Score		<sup>3</sup> Age-Matched (%) Z-Score		<sup>4</sup> BMC (g)	Area (cm <sup>2</sup> )
Radius UD	0,298	79	-2,2	87	-1,2	1,08	3,62	
Ulna UD	0,197	-	-	-	-	0,44	2,24	
Radius 33%	0,619	87	-1,3	96	-0,4	1,55	2,50	
Ulna 33%	0,555	-	-	-	-	1,21	2,17	
Both UD	0,259	-	-	-	-	1,52	5,86	
Both 33%	0,589	-	-	-	-	2,75	4,68	
Radius Total	0,479	87	-1,4	95	-0,5	6,41	13,39	
Ulna Total	0,393	-	-	-	-	3,64	9,28	
Both Total	0,444	-	-	-	-	10,06	22,67	

FIGURE 2C. 1/3 distal radius of left arm

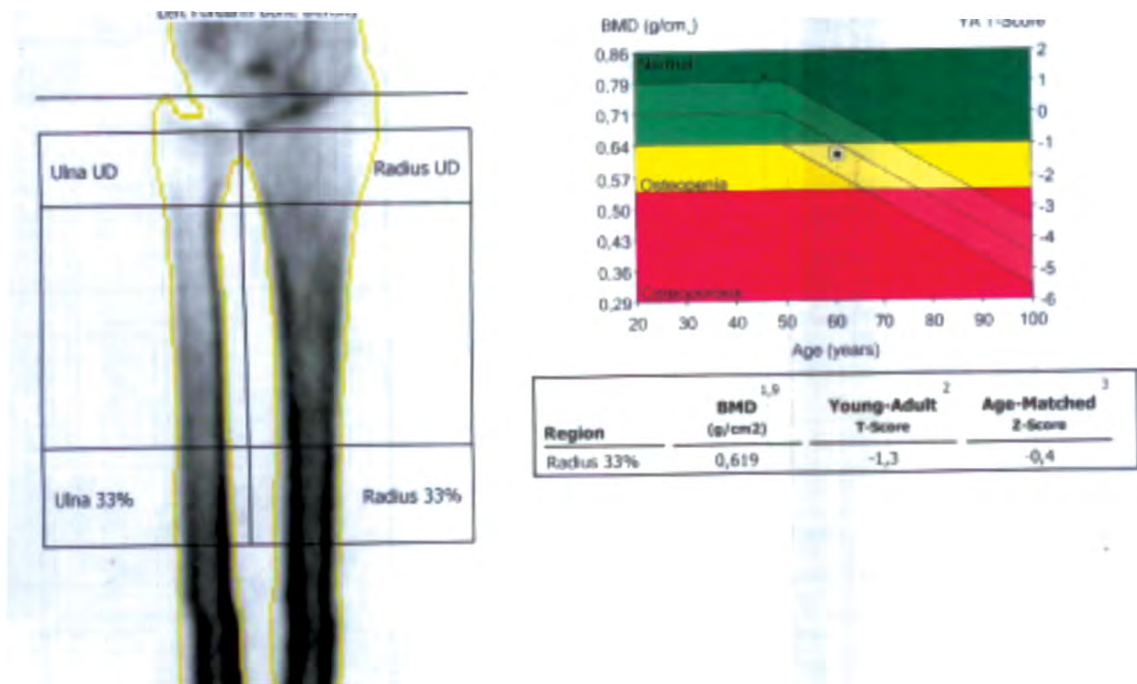


FIGURE 2A, B, C. Osteoporosis at central DXA in a menopausal woman with obesity treated with bariatric surgery

age (13,14,15). The control of cortisol excess after adrenalectomy might improve the mentioned parameters including the bone status (16,17). However, the subject we mentioned had a fragility fracture after hypercortisolemia was therapeutically approached since long term effect of glucocorticoid exposure might act after the excess acts no longer in addition to menopausal status, and bariatric surgery effects on skeleton (18,19). In this case the patient was referred to bariatric surgery after the recognition of adrenal Cushing’s syndrome. Some series have been reported of unrecognized endogenous tumour –derivate hypercortisolemia before

bariatric surgery thus pre-operative endocrine assays as essential (20).

### CONCLUSION

Obesity underlines heterogeneous aspects including dermatological, metabolic, cardiovascular and endocrine conditions; some of them are dramatically improved after bariatric surgery, yet not hypovitaminosis D and osteoporosis especially in menopausal women. The prolactin excess, Cushing’s disease or just obesity itself may cause repeated skin infections or acne.

## REFERENCES

- Grupper M, Nicolau DP. Obesity and skin and soft tissue infections: how to optimize antimicrobial usage for prevention and treatment? *Curr Opin Infect Dis.* 2017 Apr;30(2):180-191.
- Valea A, Carsote M, Moldovan C, Georgescu C. Chronic autoimmune thyroiditis and obesity. *Archives of the Balkan Medical Union.* 2018; 53(1):64-69.
- Poiana C, Radoi V, Carsote M, Bilezekian J. New Clues that May Link Osteoporosis to the Circulating Lipid Profile. *Bone Research* 2013; 1(3):260-266.
- Alamanda VK, Springer BD. The prevention of infection: 12 modifiable risk factors. *Bone Joint J.* 2019 Jan; 101-B(1\_Supple\_A):3-9.
- Garcovich S, De Simone C, Giovanardi G, Robustelli E, Marzano AV, Peris K. Post-bariatric surgery hidradenitis suppurativa: A new patient subset associated with malabsorption and micronutritional deficiencies. *Clin Exp Dermatol.* 2019 Apr; 44(3):283-289.
- Carsote M, Petrescu R, Nica AE, Ghemigian A, Paduraru DN, Valea A. Bariatric surgery and osteoporosis. *Romanian Medical Journal.* 2016; LXIII(4):297-299.
- Albulescu DM, Carsote M, Ghemigian A, Popescu M, Predescu AM, Tuculina MJ, Bugala AS, Bataiosu M, Marinescu RI, Dascalu IT, Stan M, Cumpata CN, Bechir ES. Circulating 25-hydroxycholecalciferol in relationship to Central Dual-Energy X-Ray Absorptiometry Assesses. A clinical study. *Rev. Chim. (Bucharest).* 2018; 69(12):3683-3687.
- Radu L, Carsote M, Gheorghisan-Galateanu AA, Preda SA, Calborean V, Stanescu R, Gheorman V, Albulescu DM. Blood Parathyrin and Mineral Metabolism Dynamics. A clinical analyze. *Rev. Chim. (Bucharest).* 2018; 69(10):2754-2758.
- Benaiges D, Goday A, Pedro-Botet J, Más A, Chillarón JJ, Flores-Le Roux JA. Bariatric surgery: to whom and when? *Minerva Endocrinol.* 2015 Jun; 40(2):119-28.
- Harbeck B, Danneberg S, Rahvar AH, Monig H, Haas CS. Prevalence and Predictors of Overweight and Obesity in Patients with Pituitary Dysfunctions. *Endocr Metab Immune Disord Drug Targets.* 2016; 16(4):249-253.
- Poiana C, Chirita C, Carsote M, Hortopan D, Goldstein A. Galactocele and prolactinoma – A pathogenic association?, *Maturitas.* 2009; 62(1):98-102.
- van der Valk ES, van den Akker ELT, Savas M, Kleinendorst L, Visser JA, Van Haelst MM, Sharma AM, van Rossum EFC. A comprehensive diagnostic approach to detect underlying causes of obesity in adults. *Obes Rev.* 2019 Jun; 20(6):795-804.
- Gheorghiu M, Hortopan D, Dumitrascu A, Caragheorghopol A, Stefanescu A, Trifanescu R, Niculescu D, Baci I, Carsote M, Poiana C, Badiu C, Coculescu M. Age-related endocrine tumors: nonfunctioning adrenal tumors as compared to pituitary adenomas. *Acta Endocrinologica,* 2009; V(3):371-384.
- Trifanescu R, Carsote M, Caragheorghopol A, Hortopan D, Dumitrascu A, Dobrescu M, Poiana C. Screening for secondary endocrine hypertension in young patients. *Maedica (Buchar).* 2013 Jun; 8(2):108-15.
- Poiana C, Chirita C, Carsote M, Hortopan D, Ioachim D, Corneci CM, Stanescu B. Adrenal and Pituitary Incidentalomas in a Case of Cushing's Syndrome. *Chirurgia* 2013; 6(108):886-891.
- Valea A, Ghervan C, Carsote M, Albu SE, Georgescu CE. Different surgical options in Cushing's disease. *Journal of Surgical Sciences.* 2016; 3(1):39-43.
- Paduraru DN, Nica A, Carsote M, Valea A. Adrenalectomy for Cushing's syndrome: do's and don'ts. *Journal of Medicine and Life.* 2016; 4(9):334-341.
- Rahaman SH, Jyotsna VP, Kandasamy D, Shreenivas V, Gupta N, Tandon N. Bone Health in Patients with Cushing's Syndrome. *Indian J Endocrinol Metab.* 2018 Nov-Dec; 22(6):766-769.
- Kim BJ, Lee SH, Koh JM. Bone Health in Adrenal Disorders. *Endocrinol Metab (Seoul).* 2018 Mar; 33(1):1-8.
- Javorsky BR, Carroll TB, Tritos NA, Salvatori R, Heaney AP, Fleseriu M, Biller BM, Findling JW. Discovery of Cushing's Syndrome After Bariatric Surgery: Multicenter Series of 16 Patients. *Obes Surg.* 2015 Dec; 25(12):2306-13.